

## Highly-dosed neo-adjuvant tamoxifen improves surgical outcome in segmental fasciectomy in high risk patients with Dupuytren's disease.

*Degreef I, MD, PhD & De Smet L, MD, PhD*

**Hypothesis:** Are we able to improve the surgical outcome of strand interruptions in Dupuytren's disease by adding highly dosed neo-adjuvant tamoxifen?

**Methods:** Prospective randomised double-blind study, protocol according to the CONSORT standards, to investigate the possible adjuvant effect of tamoxifen on subtotal fasciectomy in patients with Dupuytren's disease, who show a high risk for recurrence (Abe grade 4 or more). Goniometric evolution was monitored on digital photography and satisfaction was measured on a visual analogue scale (VAS) with a preliminary 1 year follow-up.

**Results:** With the implant, the postoperative range of motion improved significantly by 32% and remained unchanged after 3 months with a 1 year follow-up. Likewise, the VAS for satisfaction improved significantly more.

**Summary:** We conclude that highly dosed neo-adjuvant tamoxifen improves the surgical outcome of segmental fasciectomy in Dupuytren's disease by achieving a better finger extension and a high patients' satisfaction.

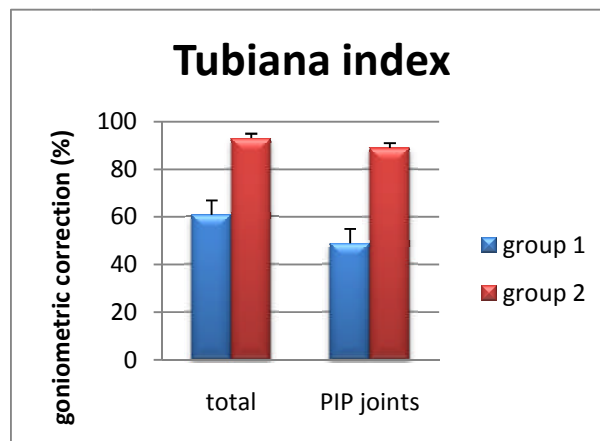


Figure 1: Comparison of the Tubiana relative correction coefficient in both groups. A significant difference ( $p = 0.001$ ) is seen in total correction, where the placebo group showed a total correction of the MCP and PIP joints of 61% (SD 26.8) (group 1) compared to 93% (SD 13.2) in the tamoxifen group. Looking at the isolated PIP joint, which is most difficult to correct, the difference is also statistically significant ( $p=0.007$ ) from 49% in group 1 towards 89% in group 2.

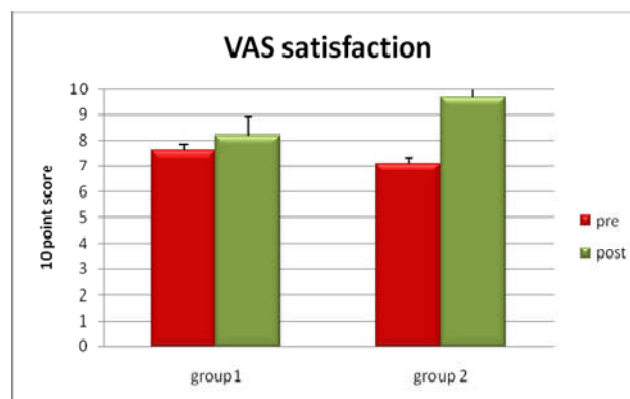


Figure 2: Illustration of the significant difference ( $p = 0.0006$ ) in postoperatively improved visual analogue scale for satisfaction in the tamoxifen patients (group 2), but not in the placebo group ( $p = 0.3$ ) (group 1).